

Clinical Cases

Prof Peet J van der Vyver

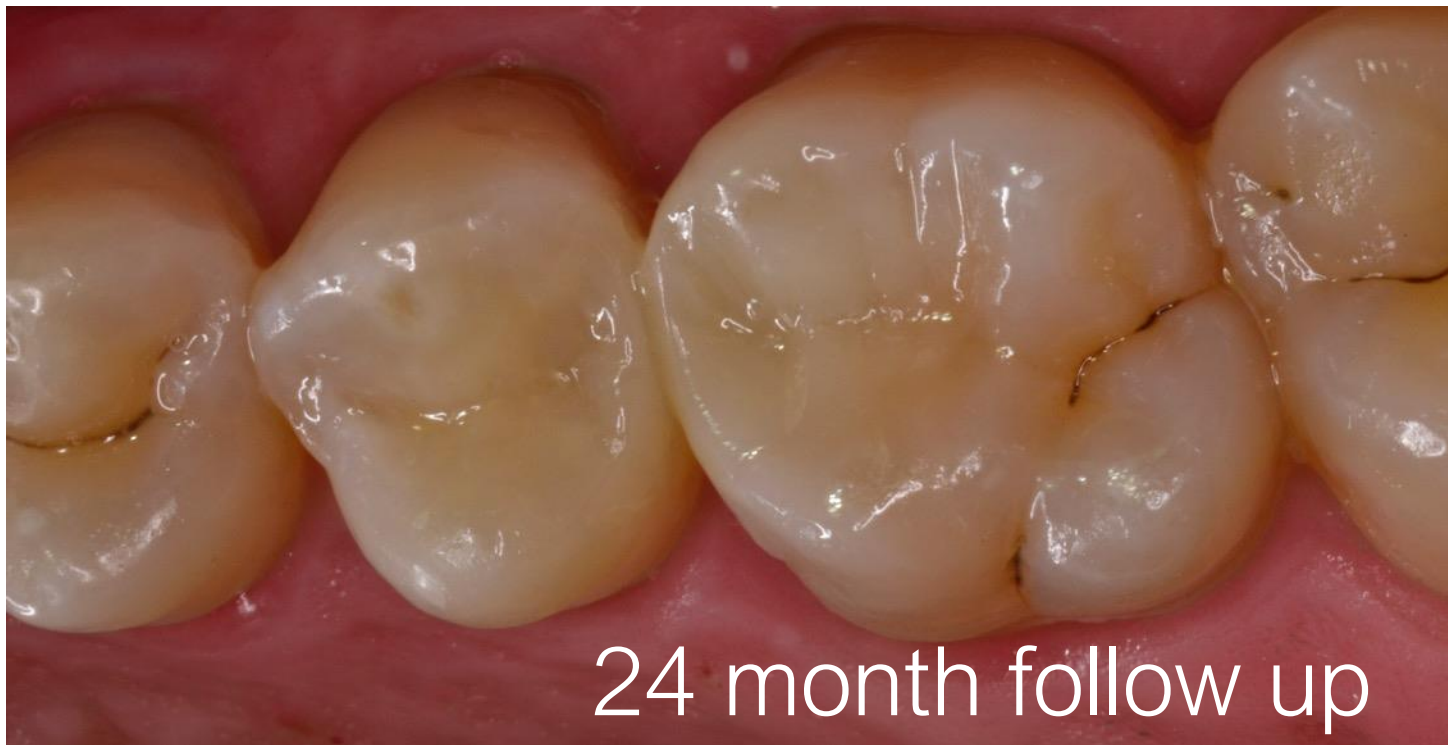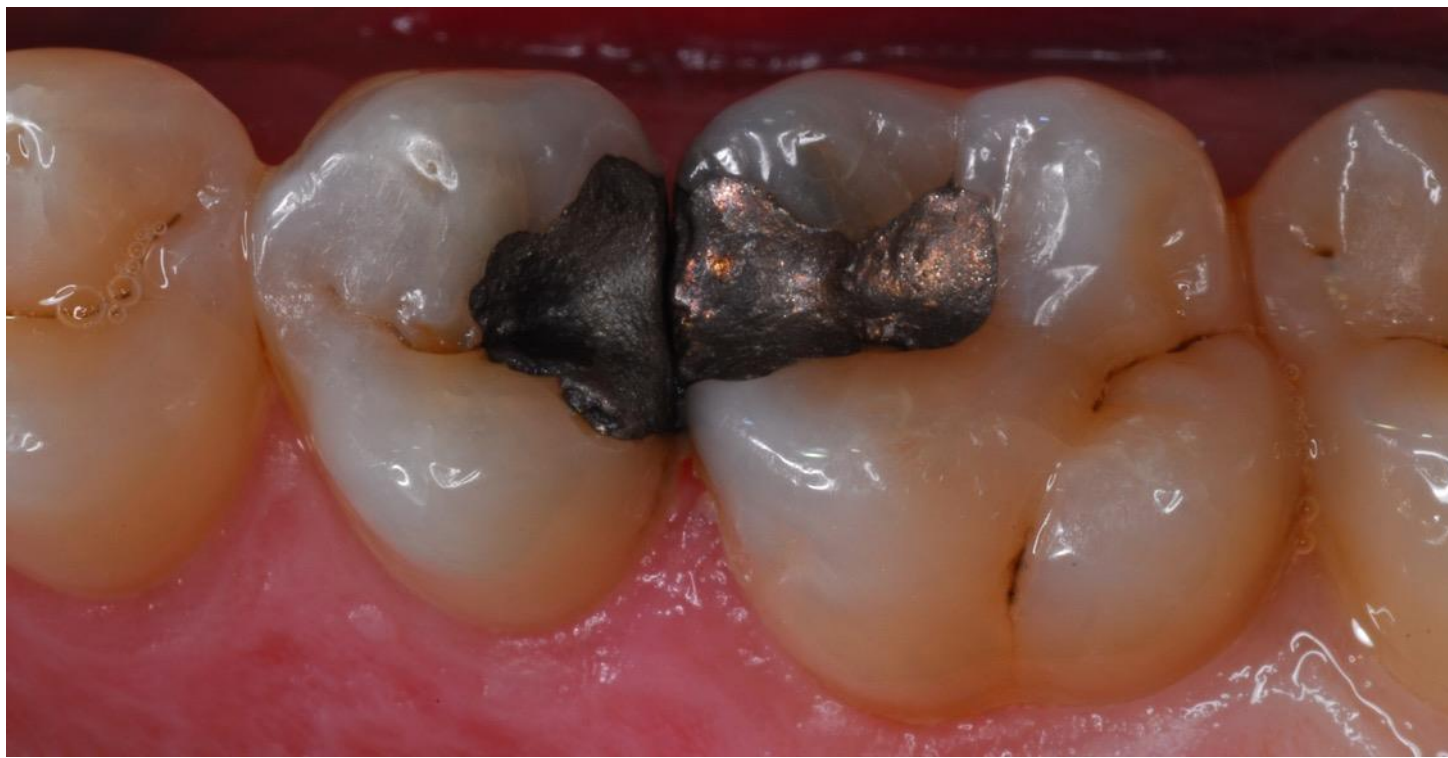University of Pretoria

Studio 4 Endodontics, Restorative Dentistry and Dental Education

South Africa

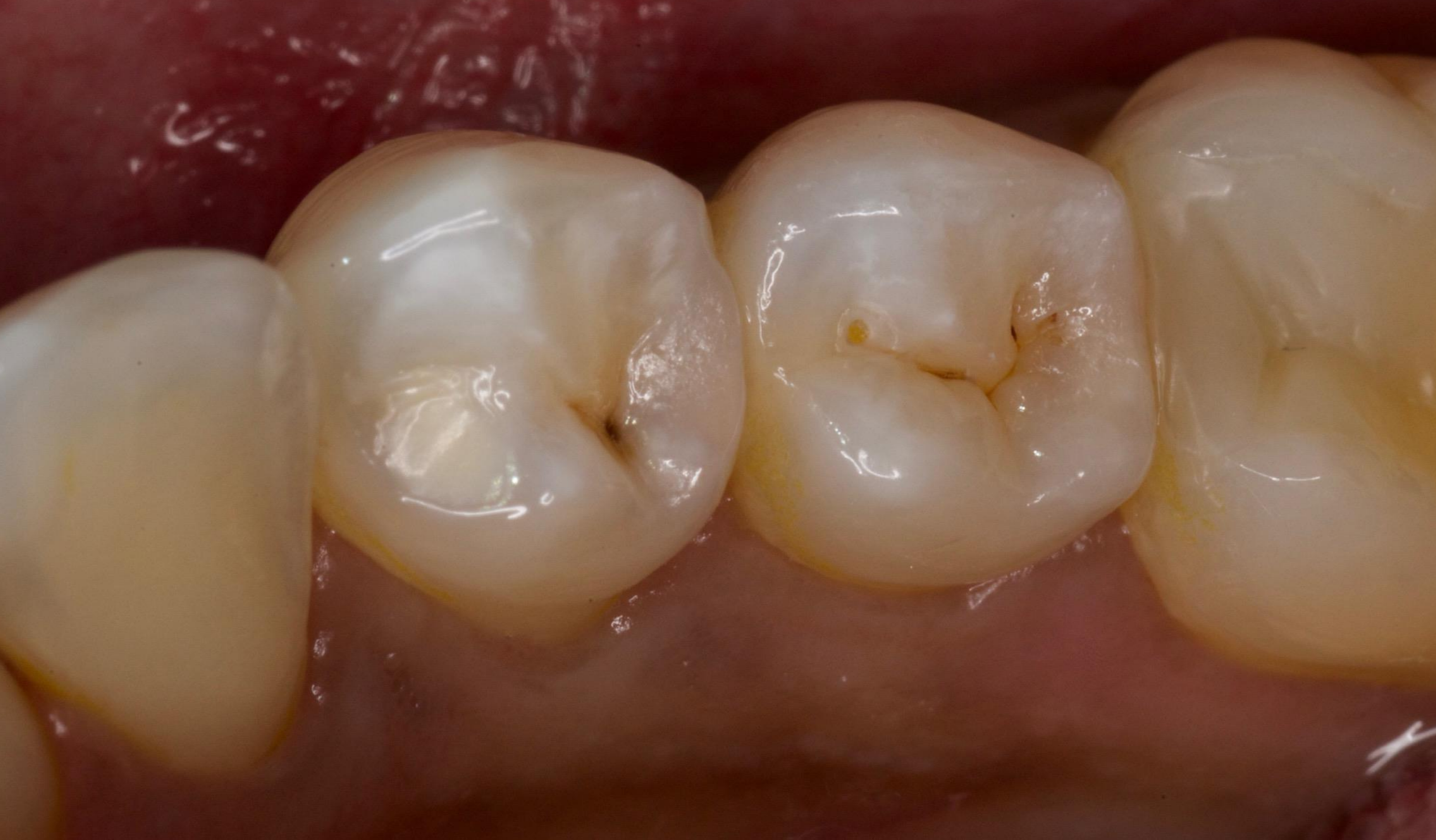Case Report 1

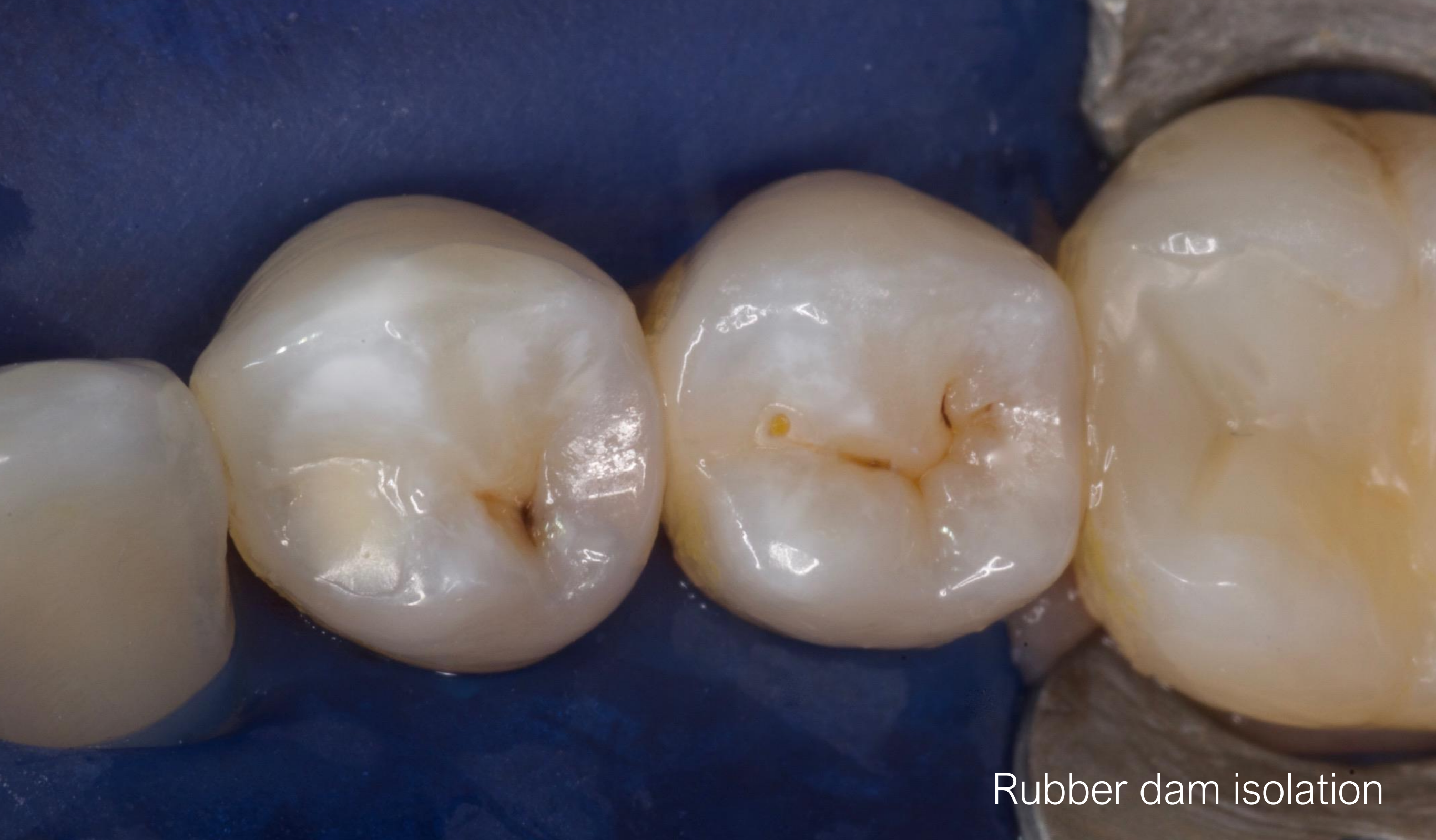Replacement of old amalgam restorations on right maxillary second premolar (DO) and first molar (MO)



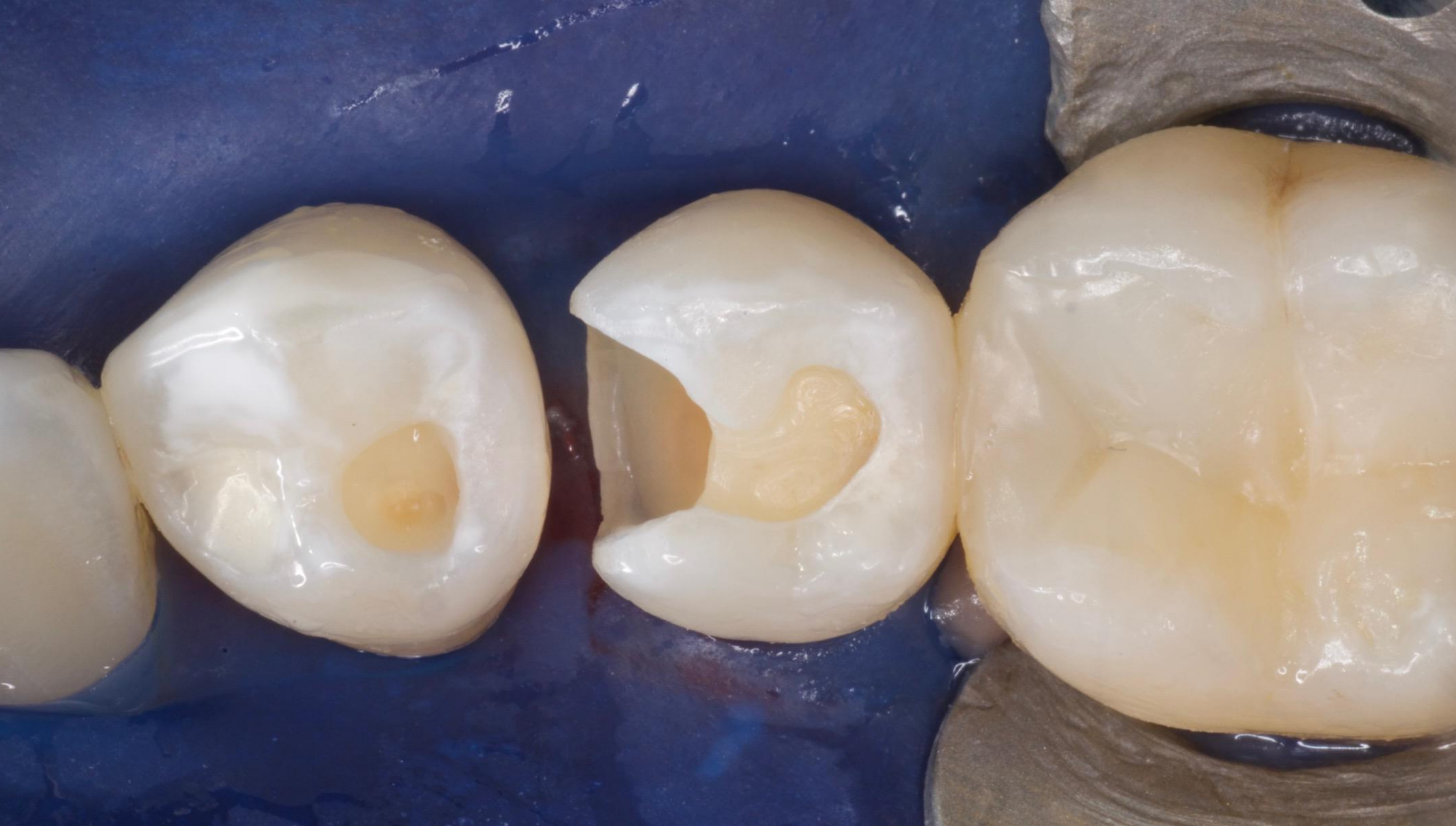Case Report 2

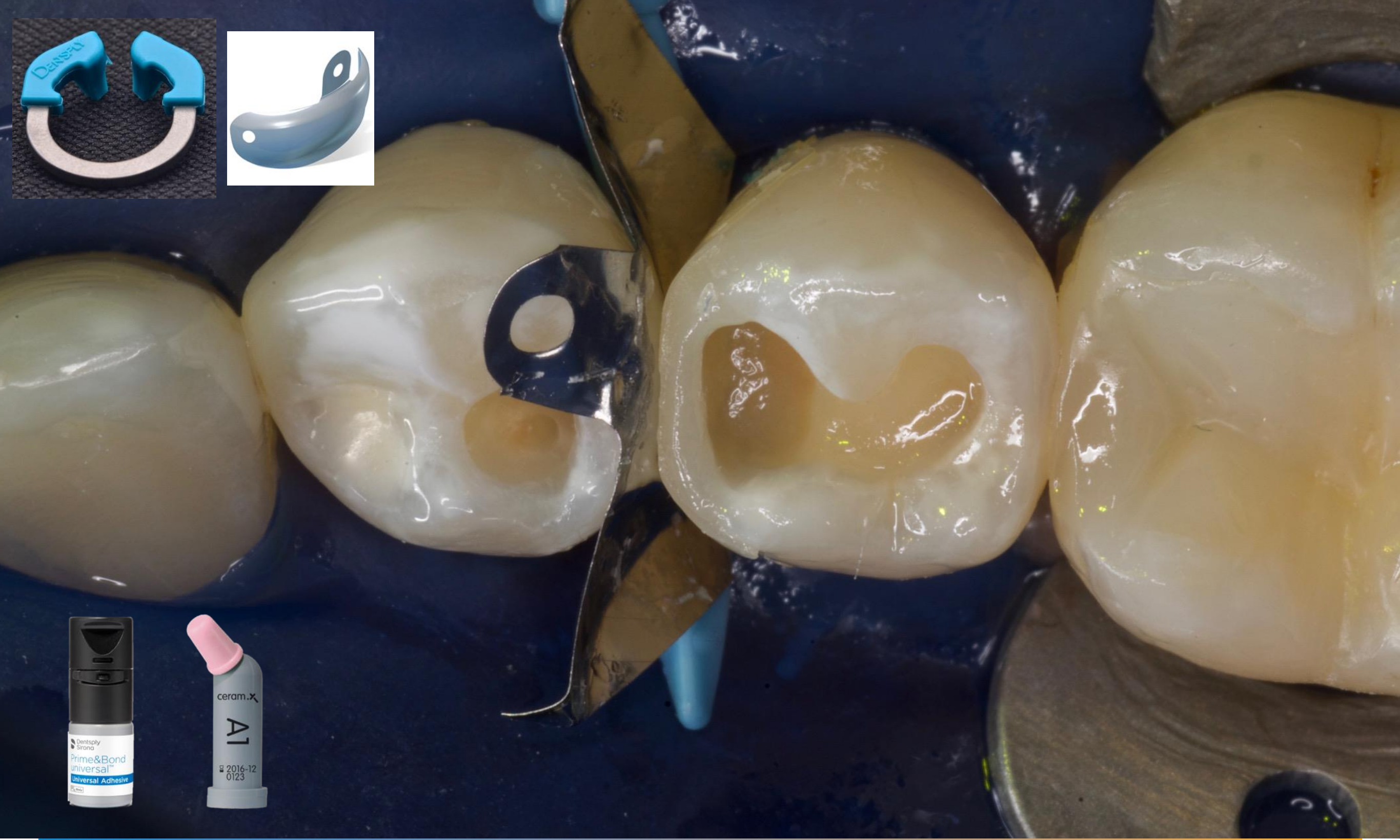Restoration of carious lesions on mandibular right first premolar (O) and second premolar (MO)

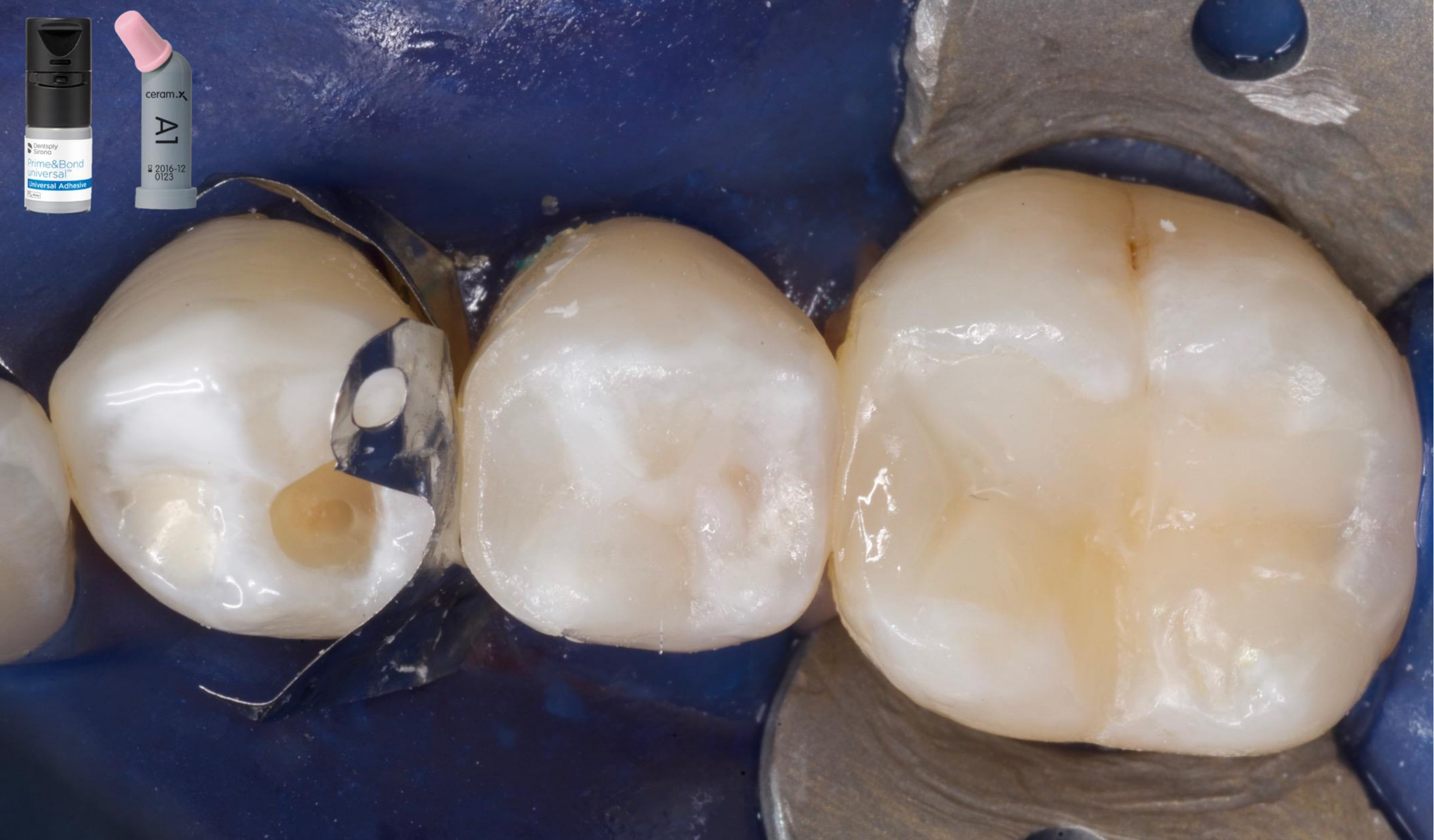


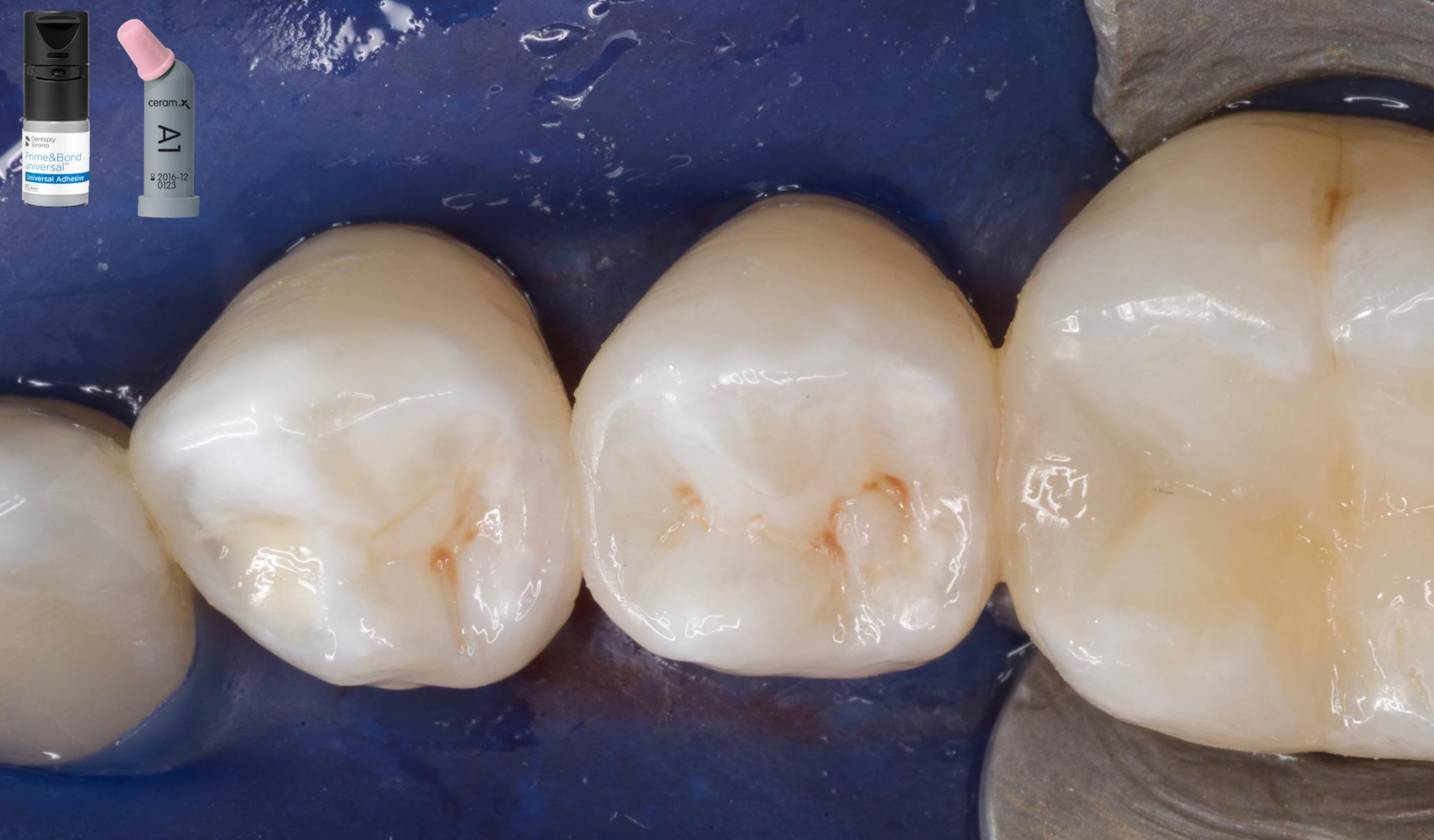
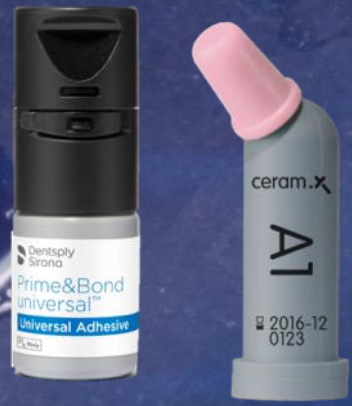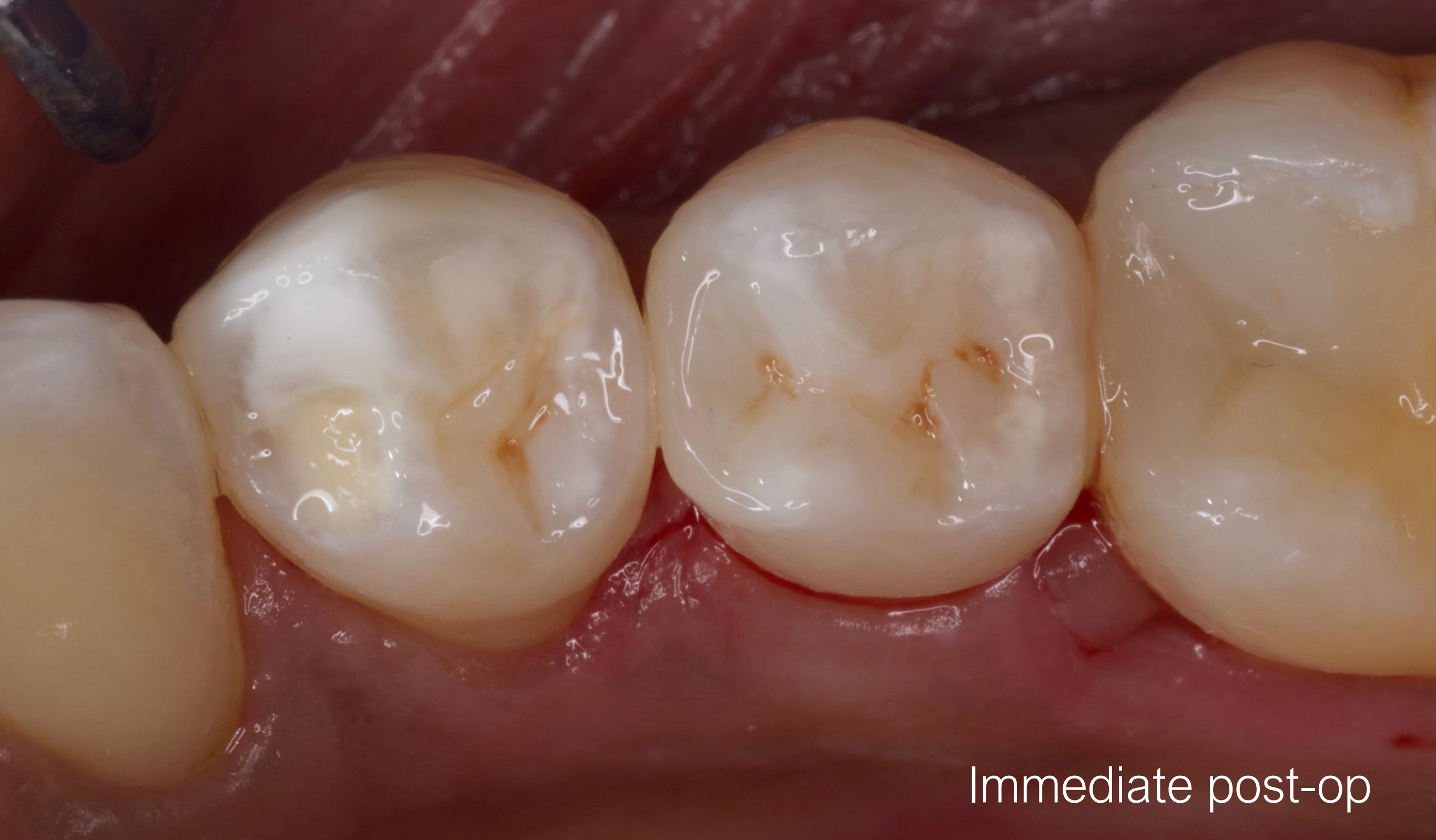Rubber dam isolation



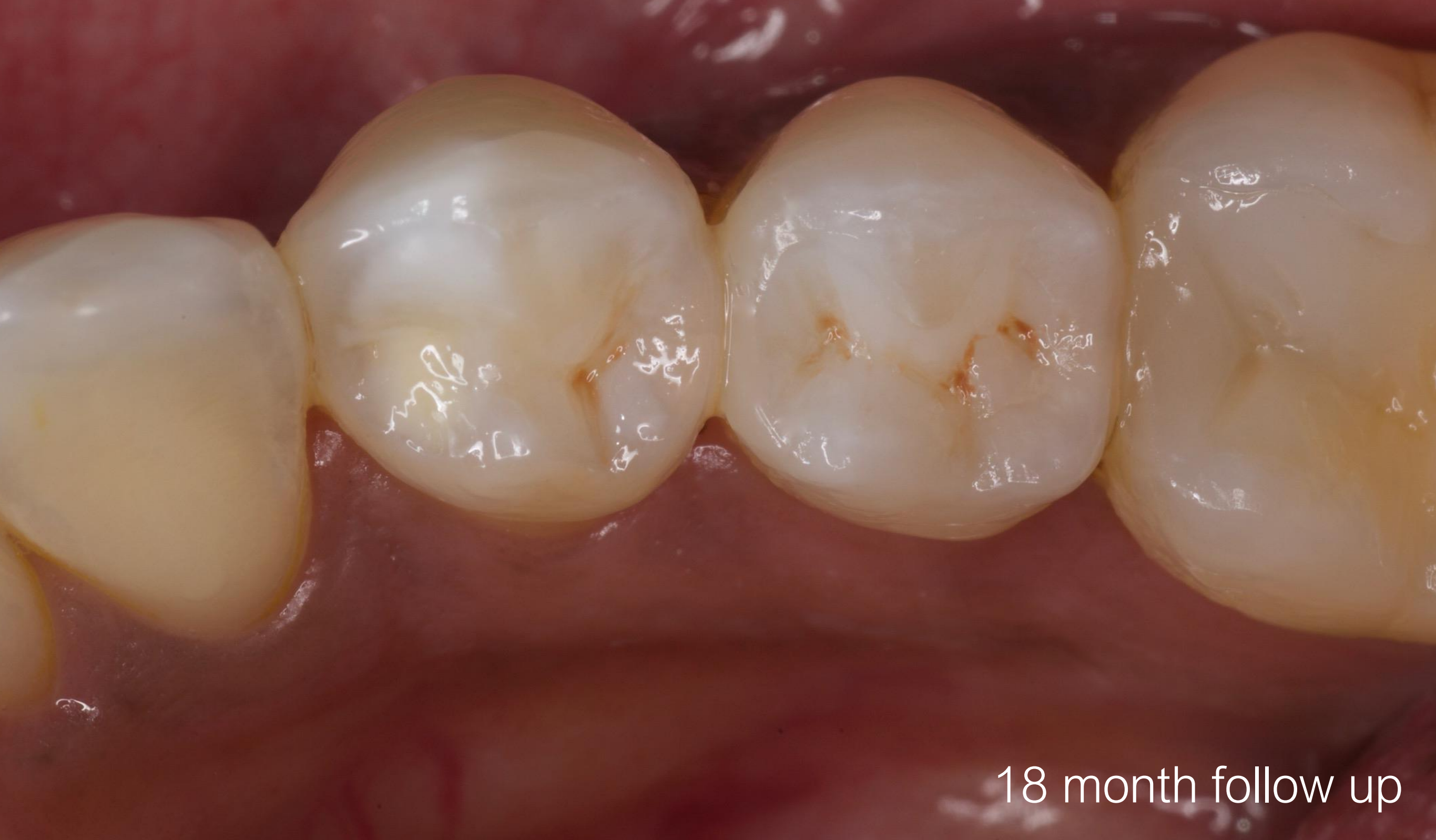







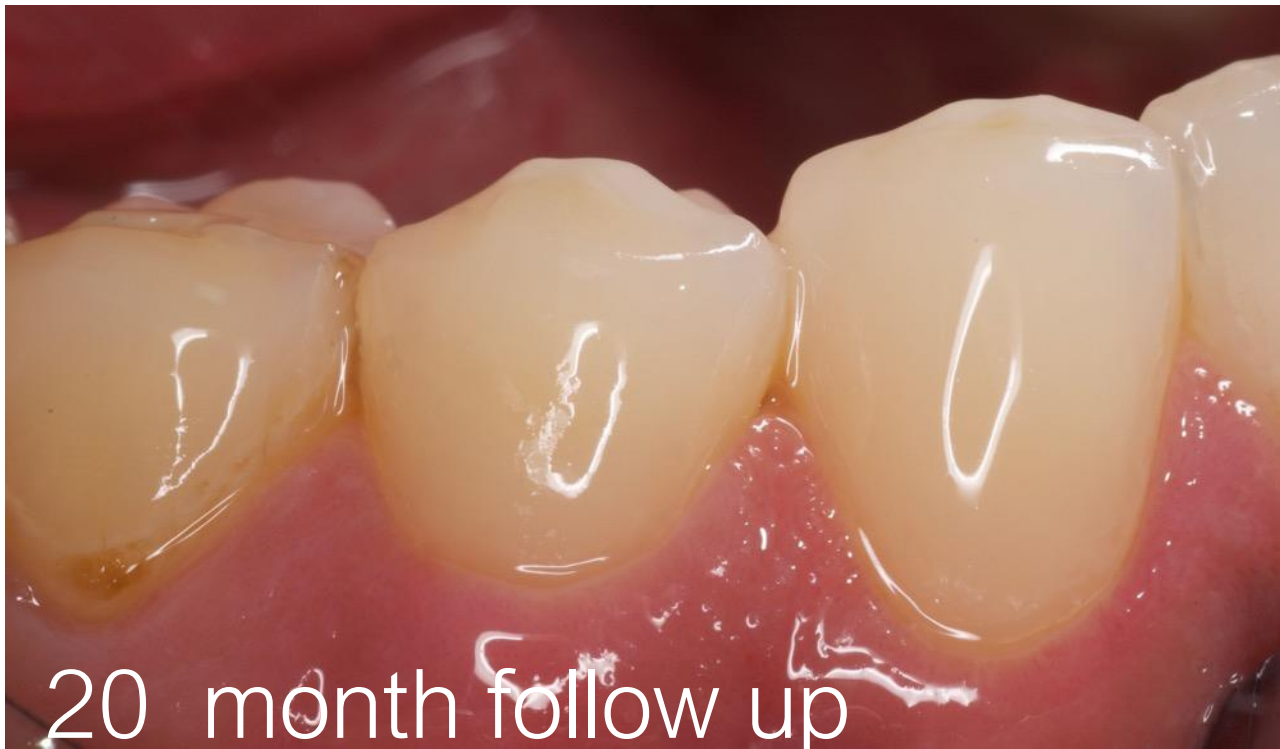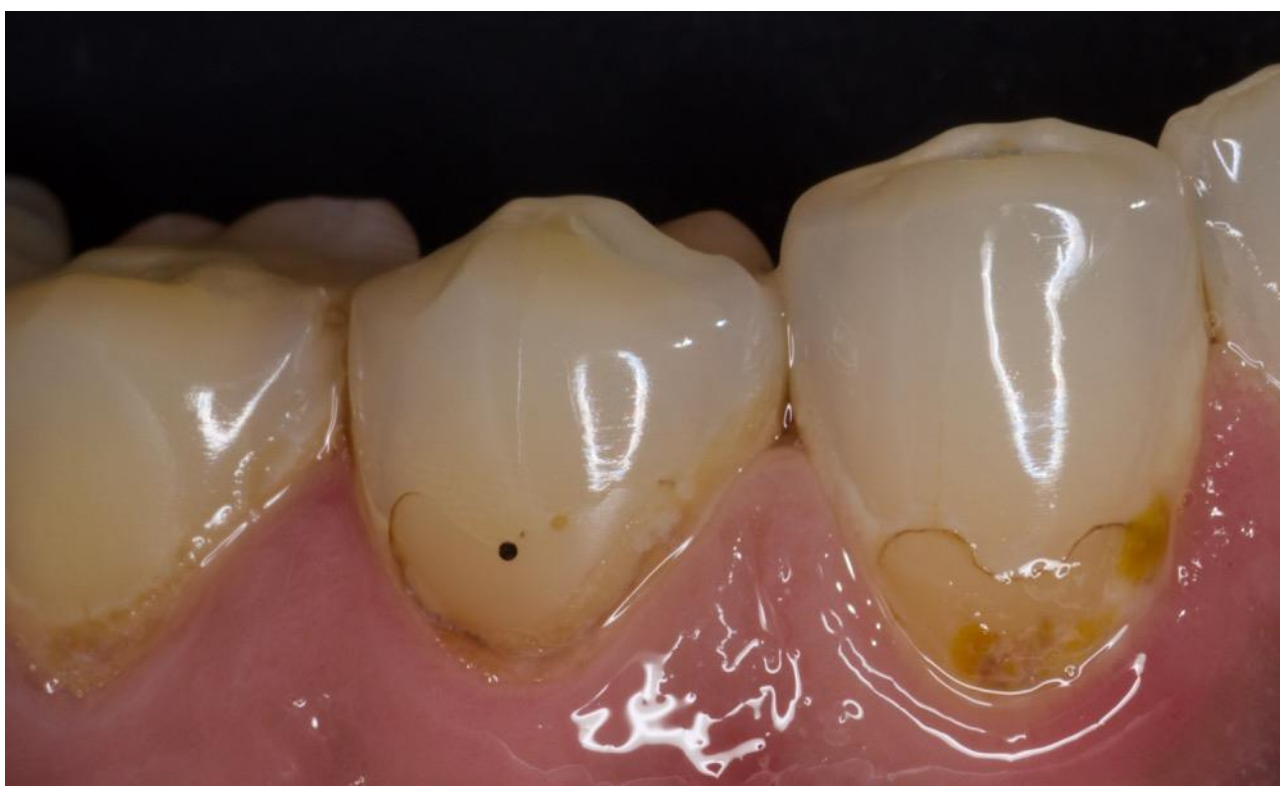Immediate post-op



18 month follow up

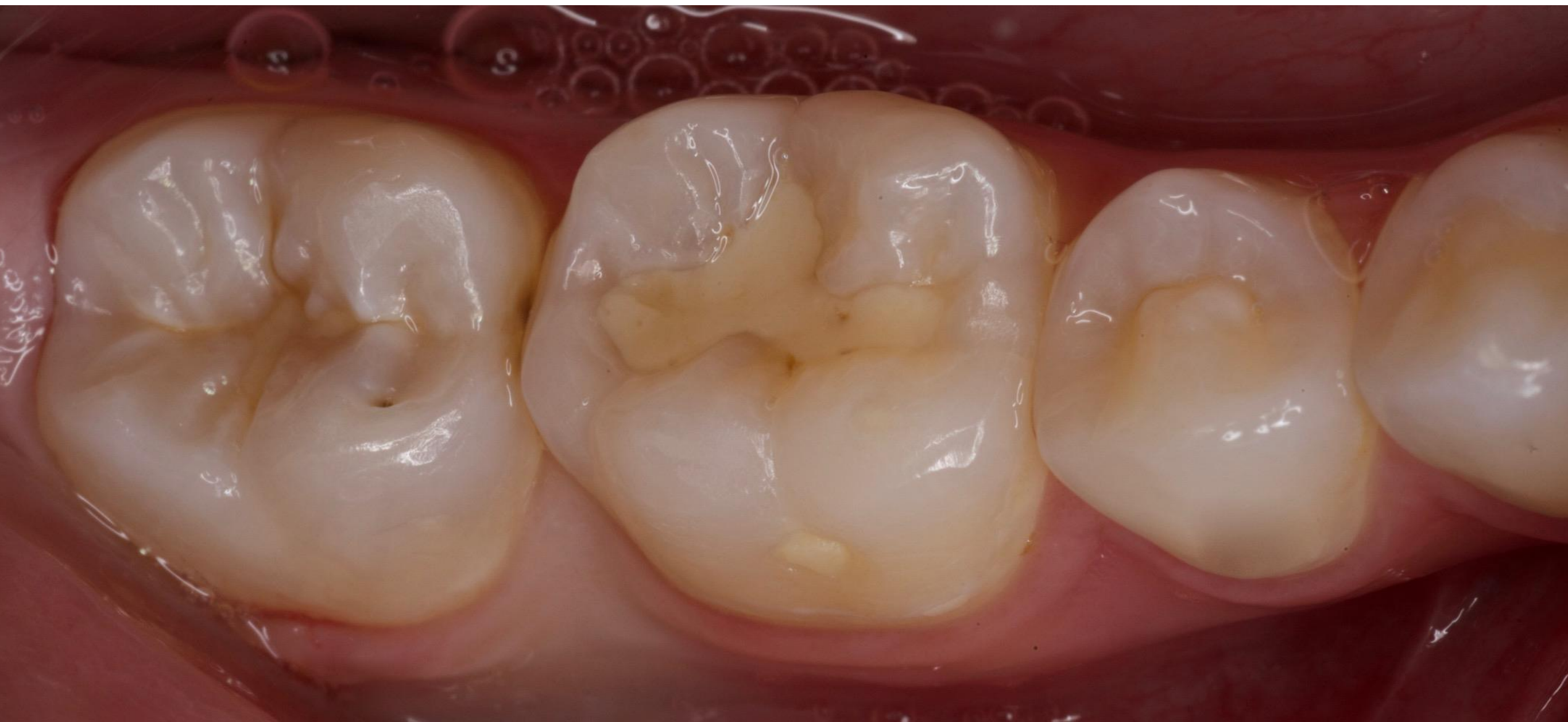Case Report 3

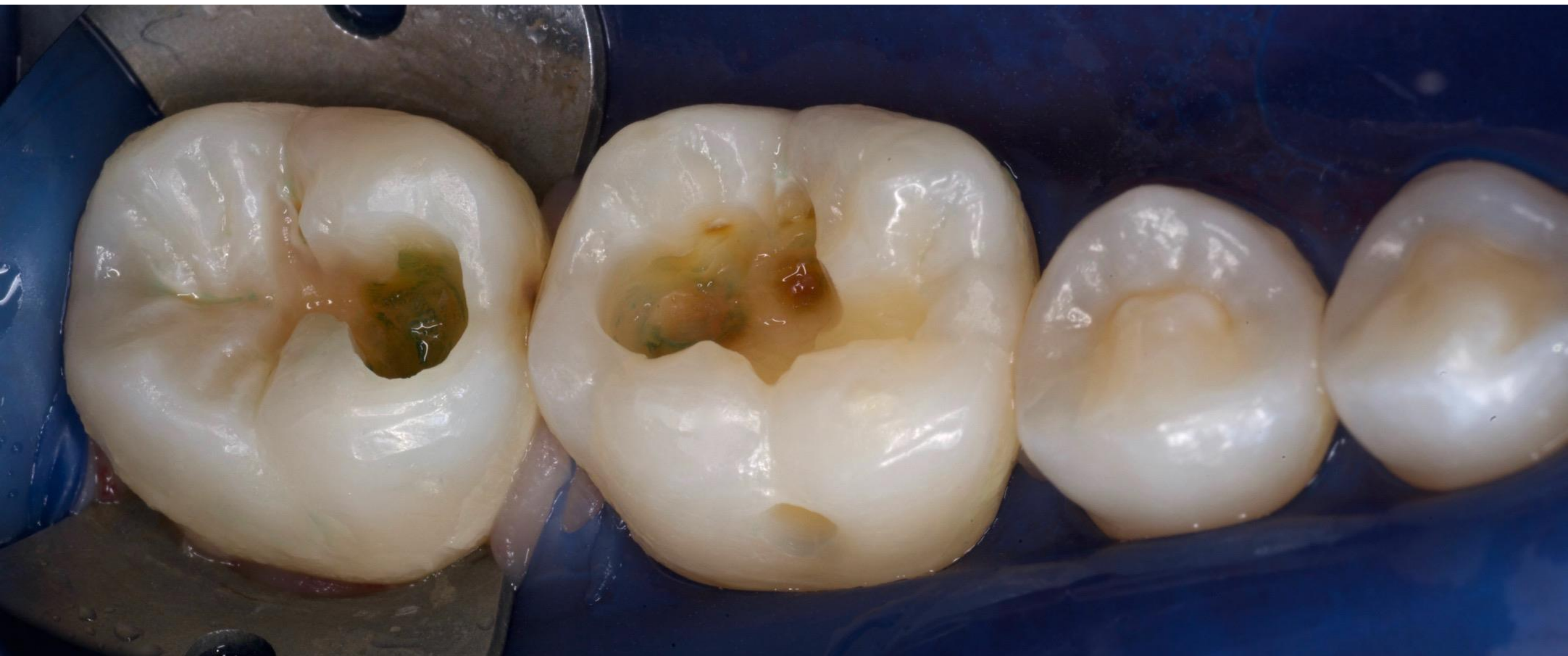Restoration of leaking buccal composite restorations on
mandibular right canine and first premolar

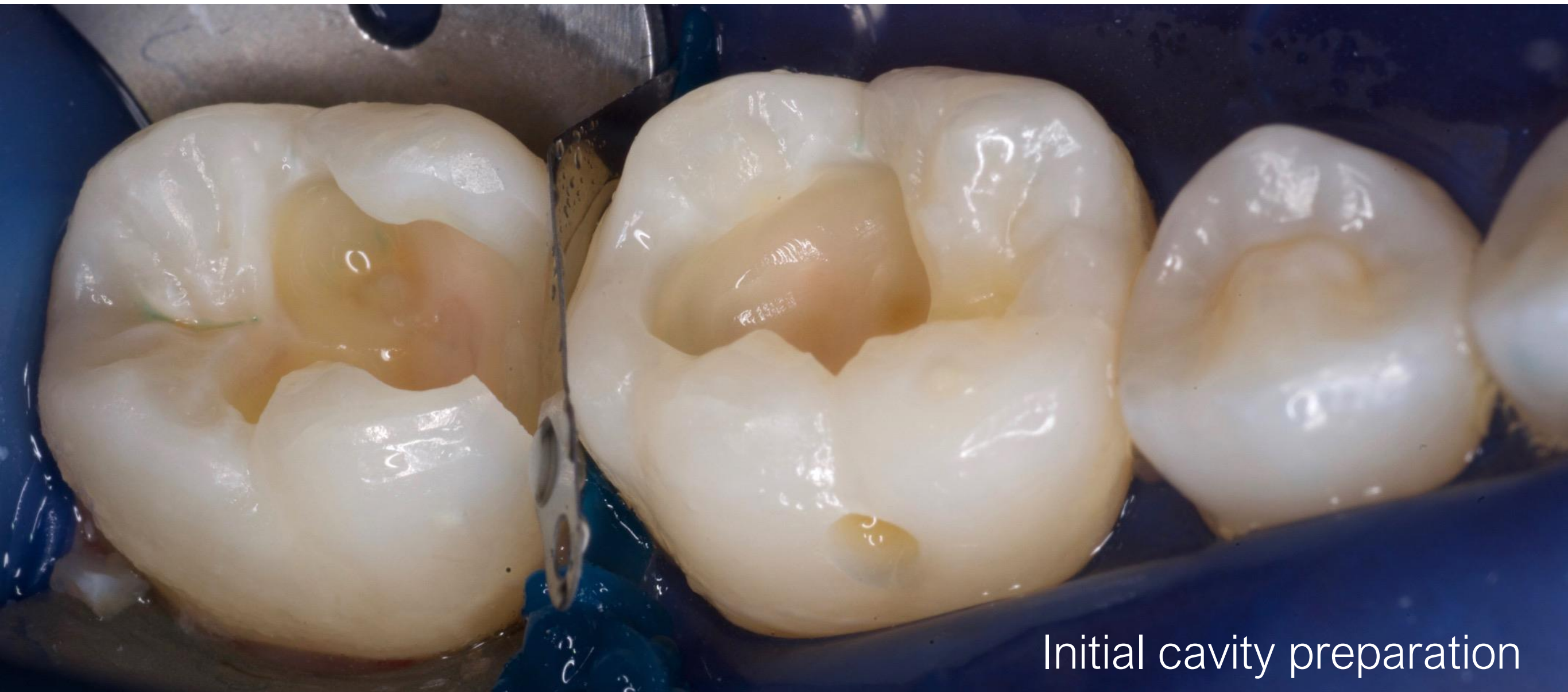

Case Report 4

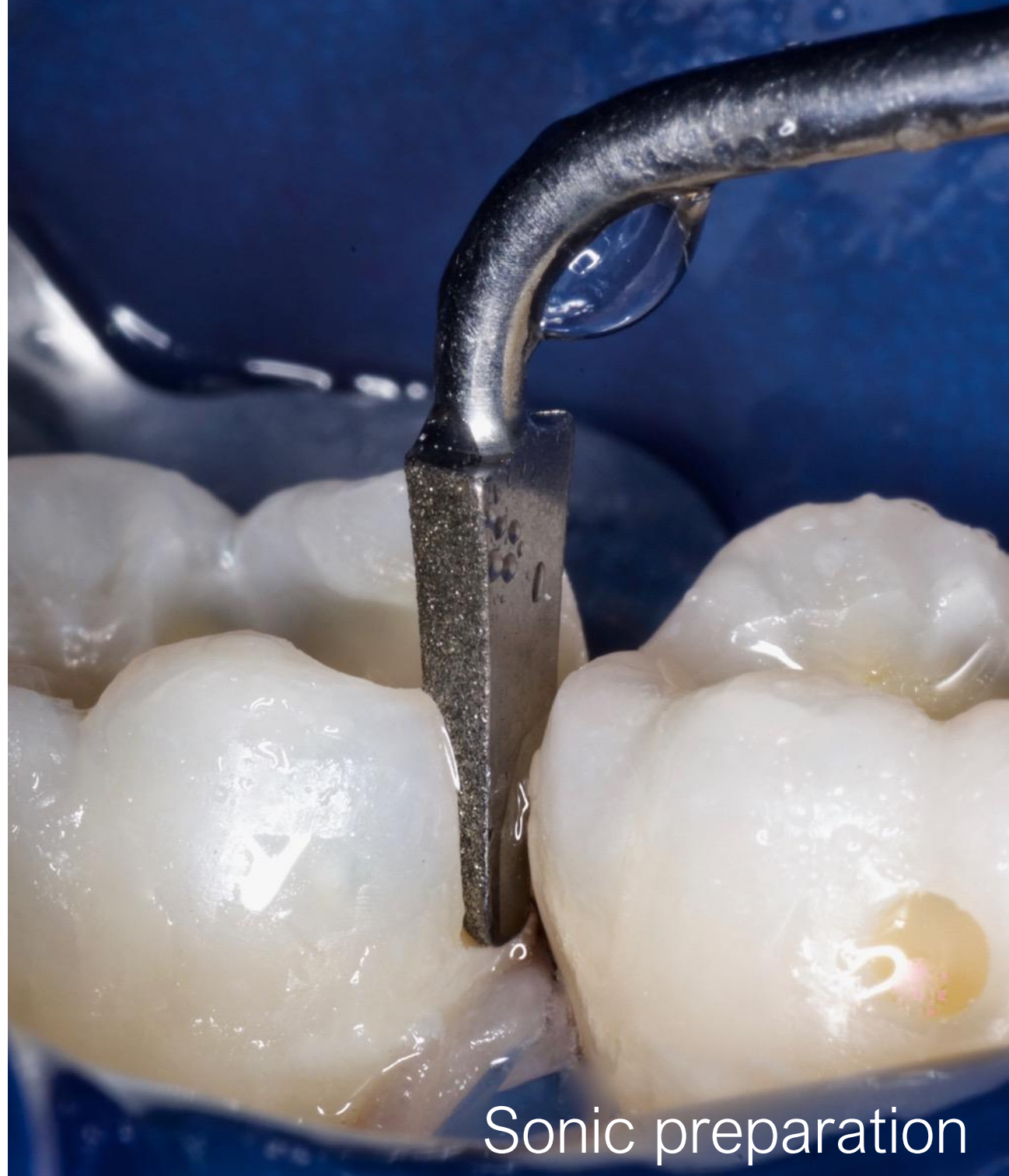Restoration of carious lesions on mandibular left first (OB) and second (MO) molars

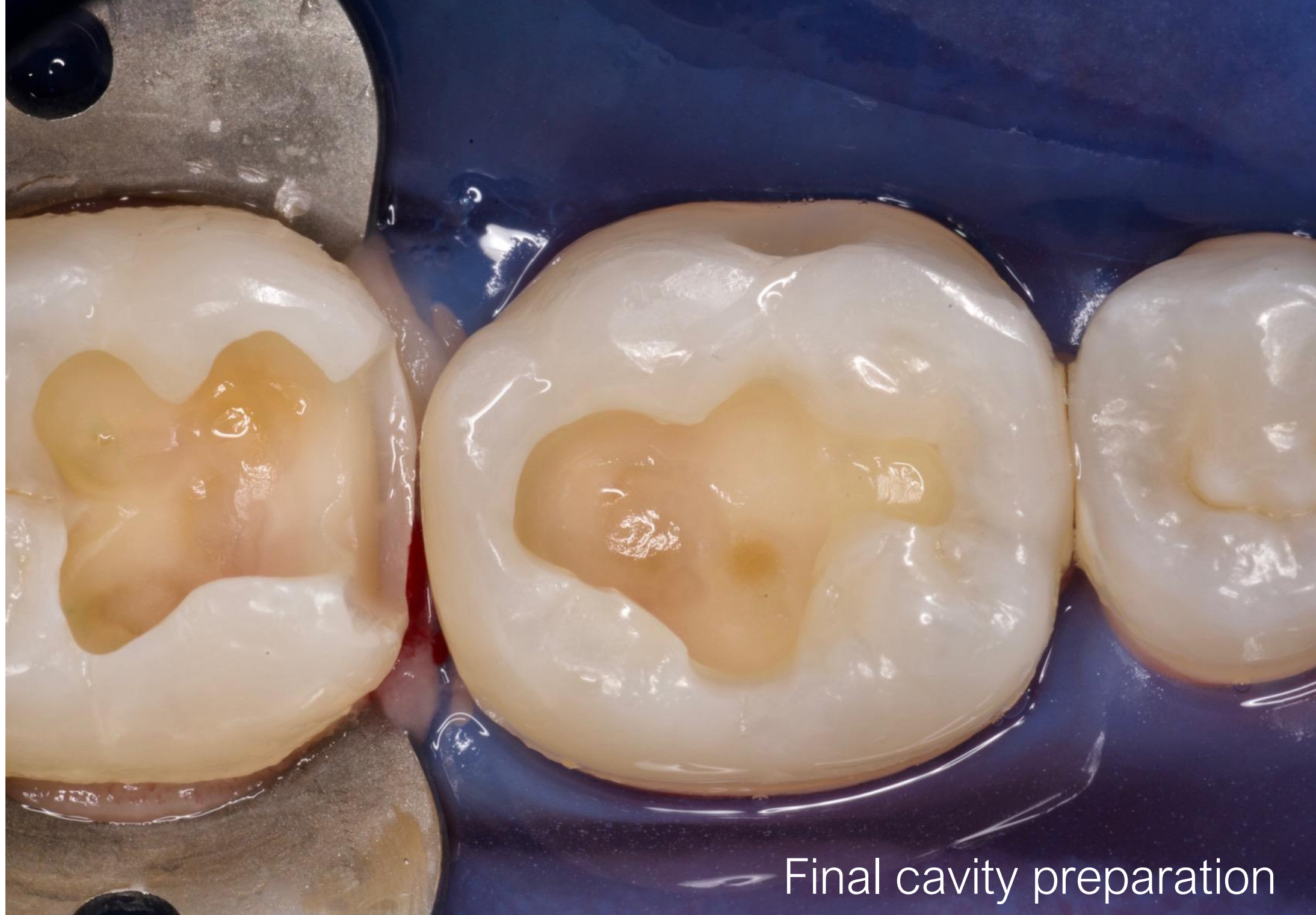




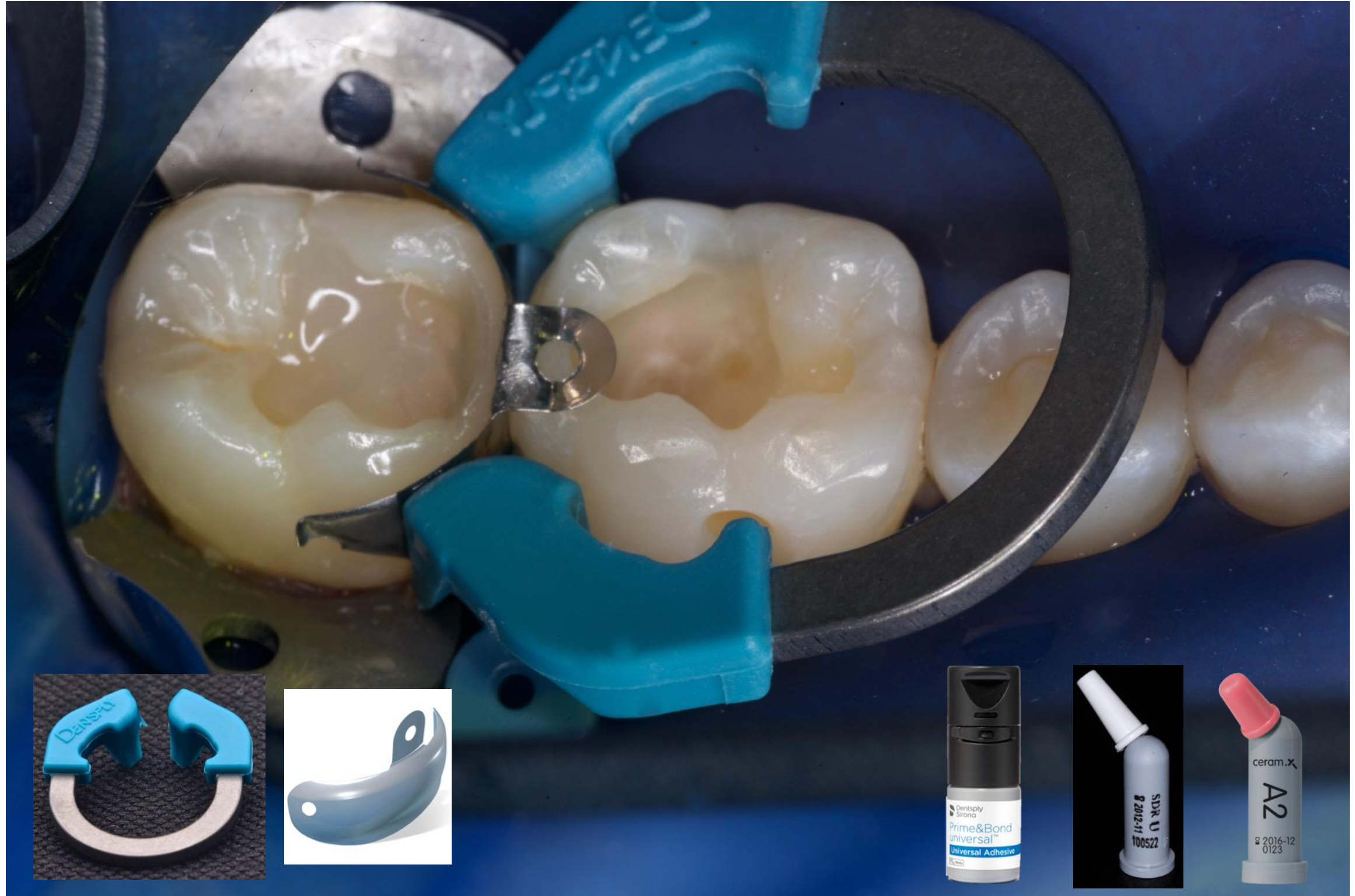
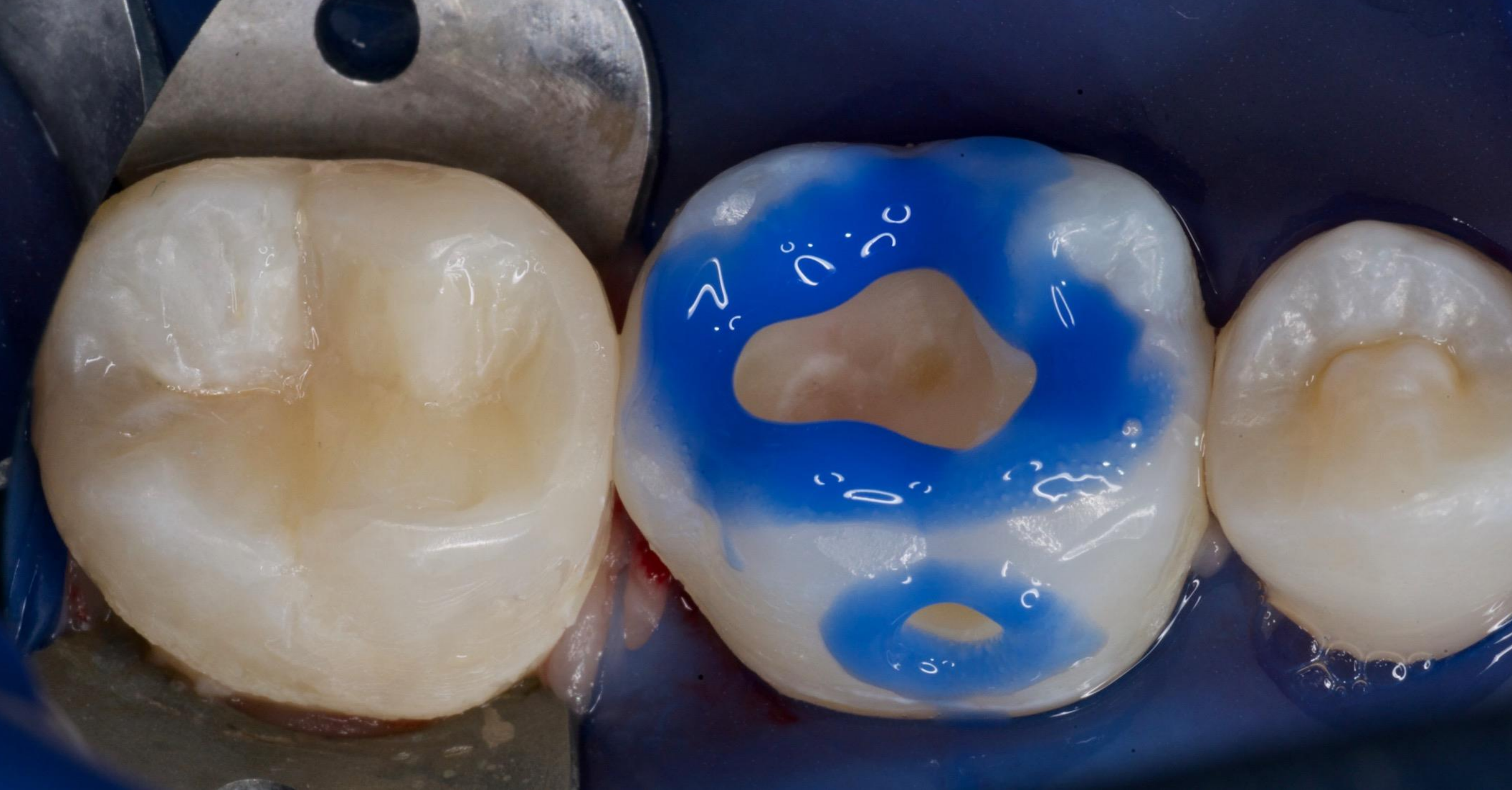Initial cavity preparation

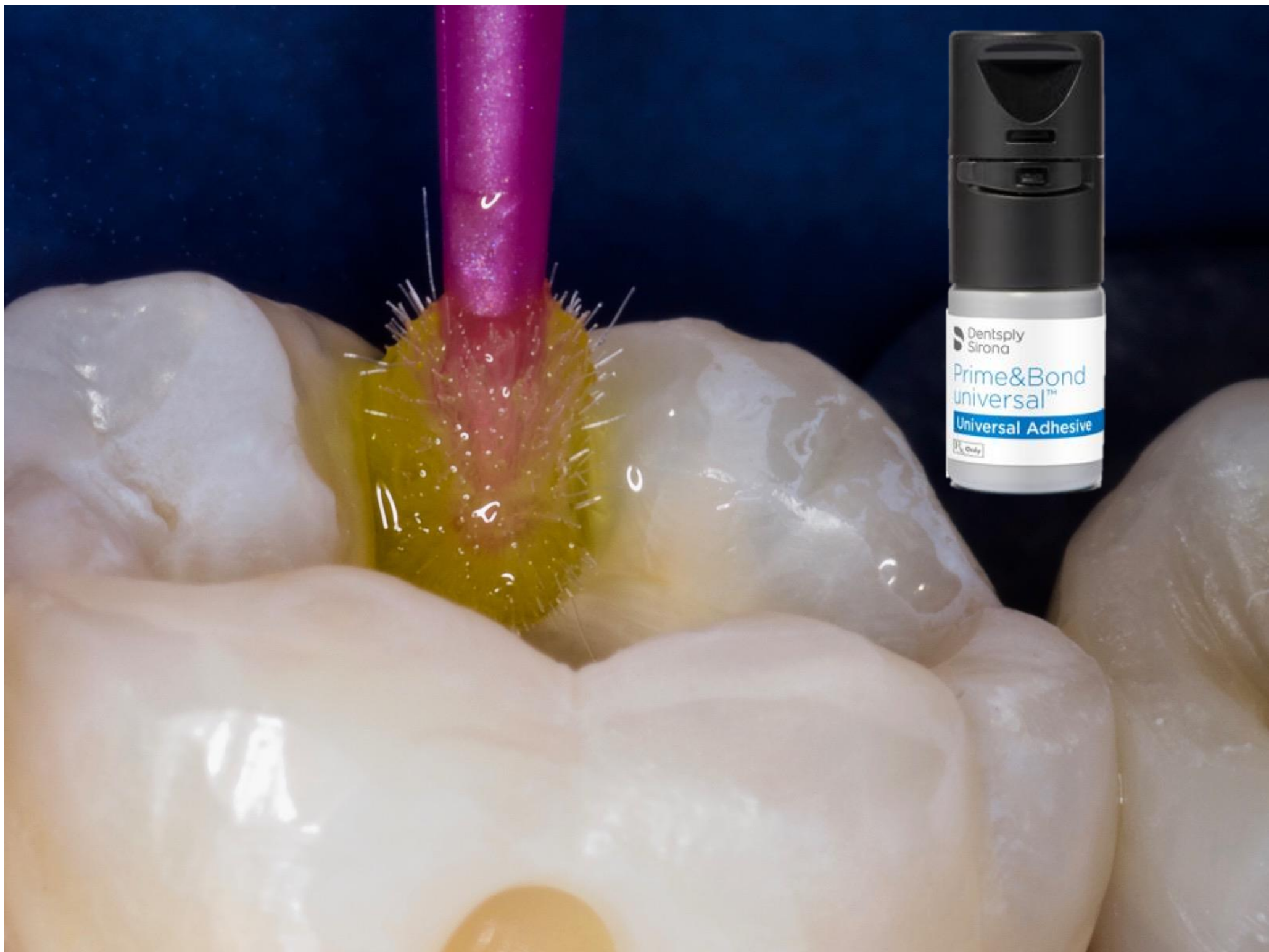

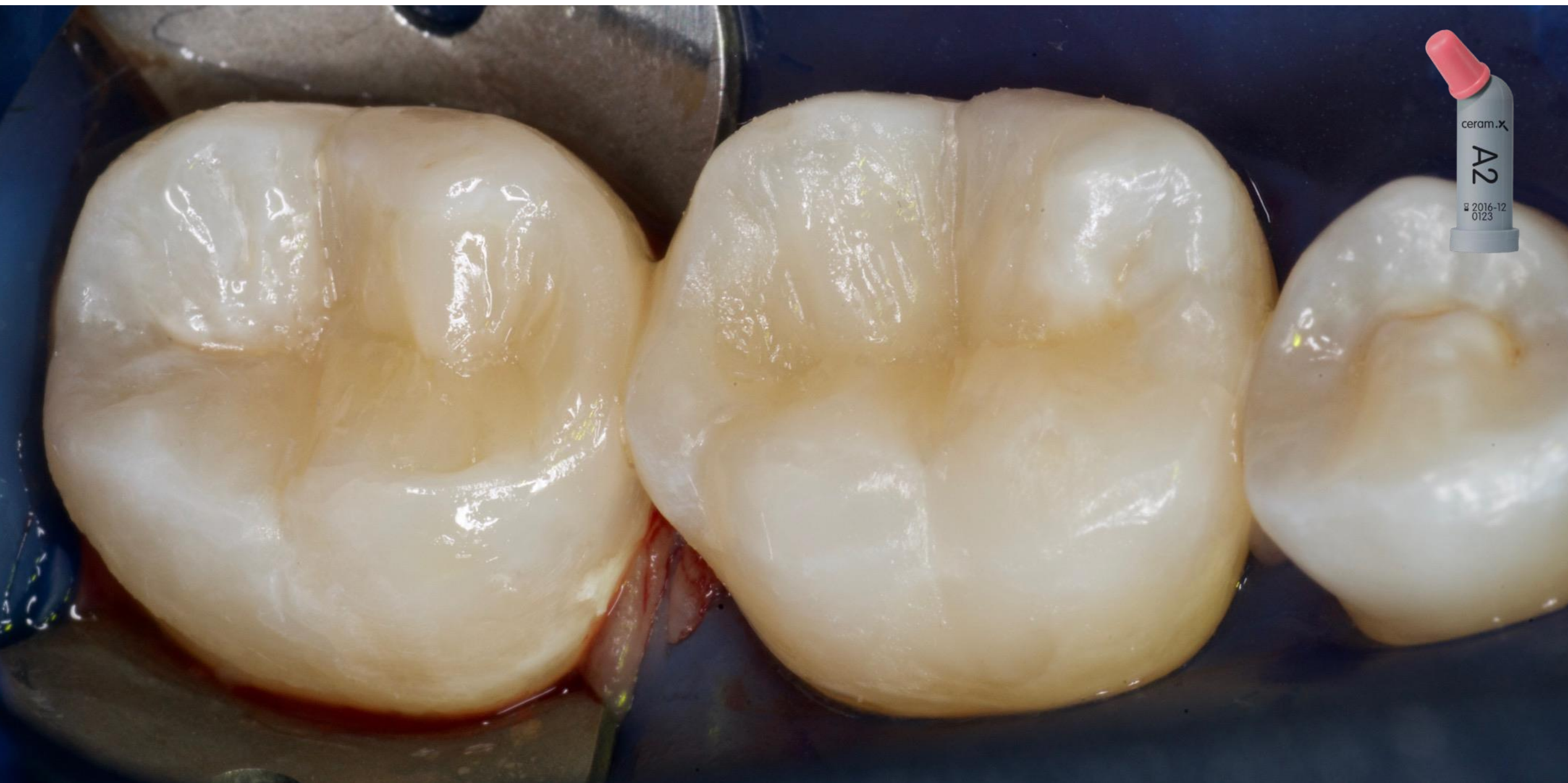


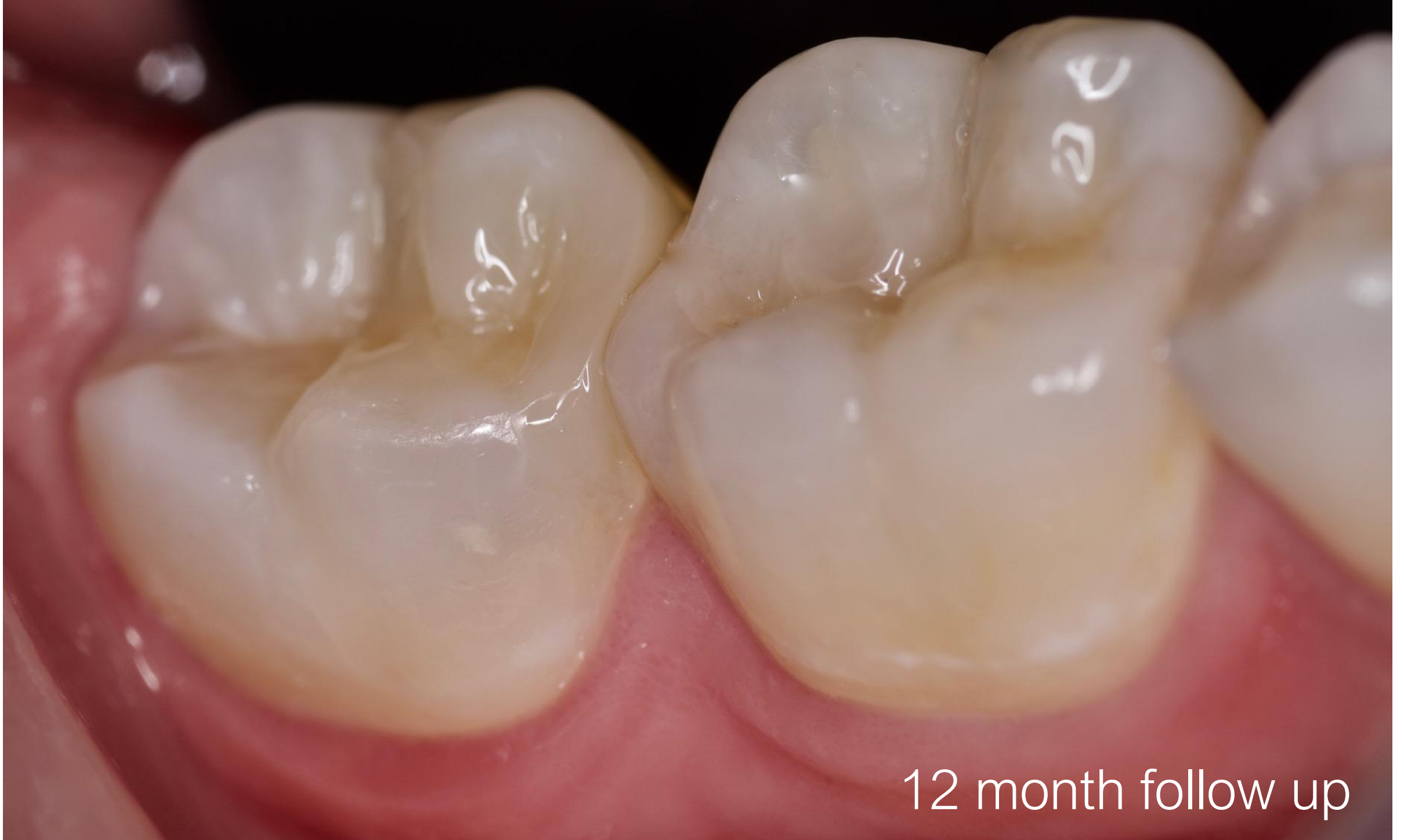Final cavity preparation



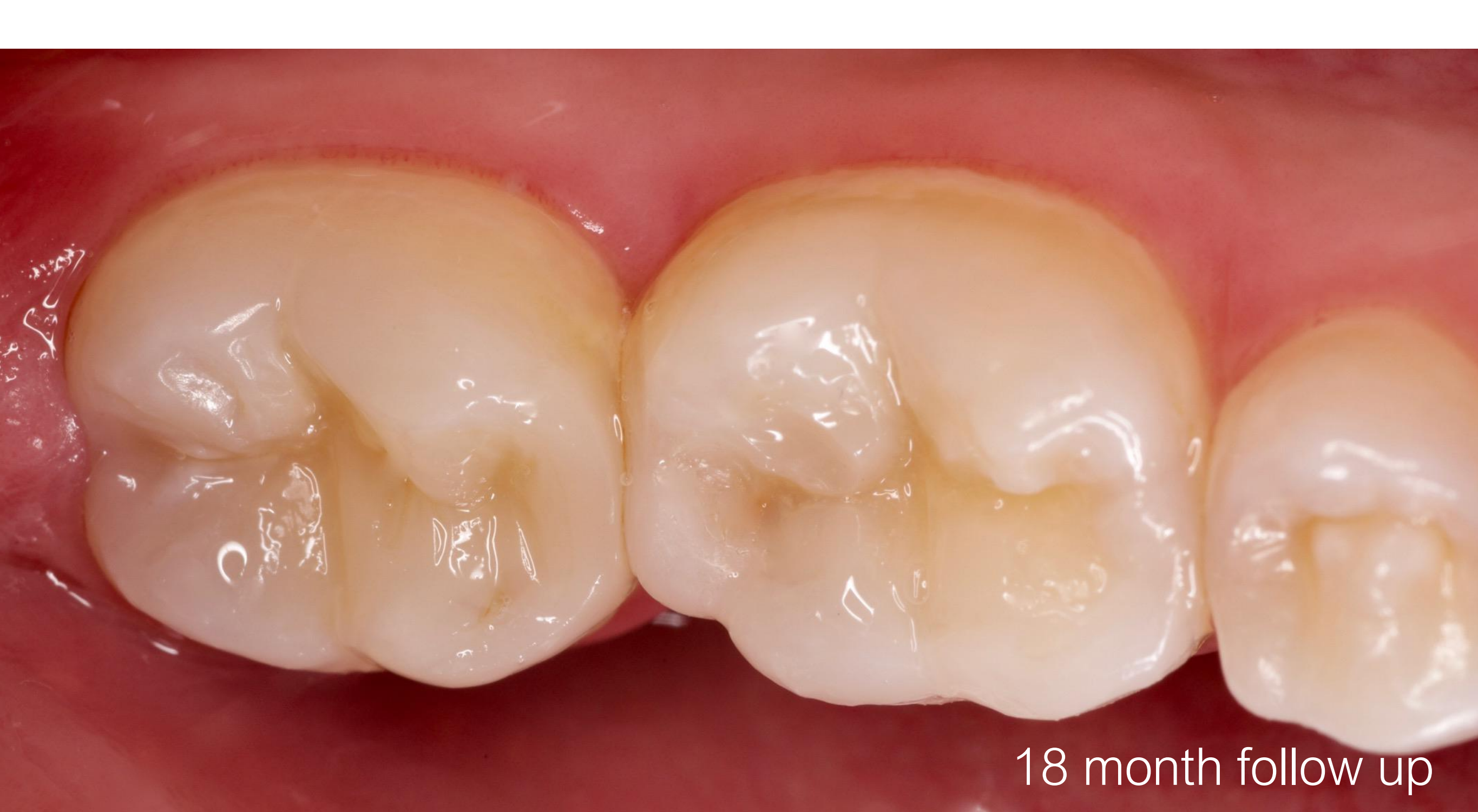







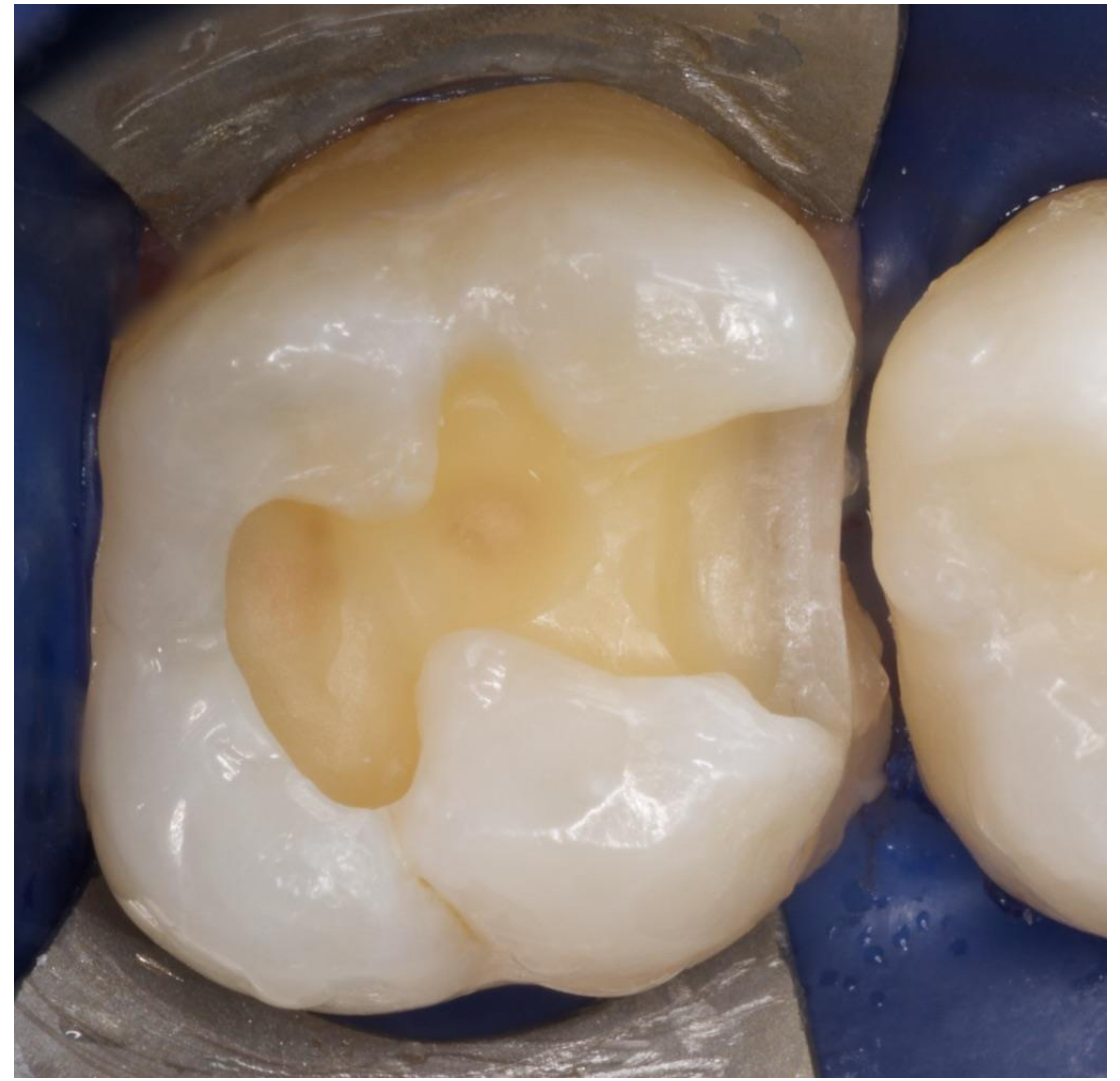
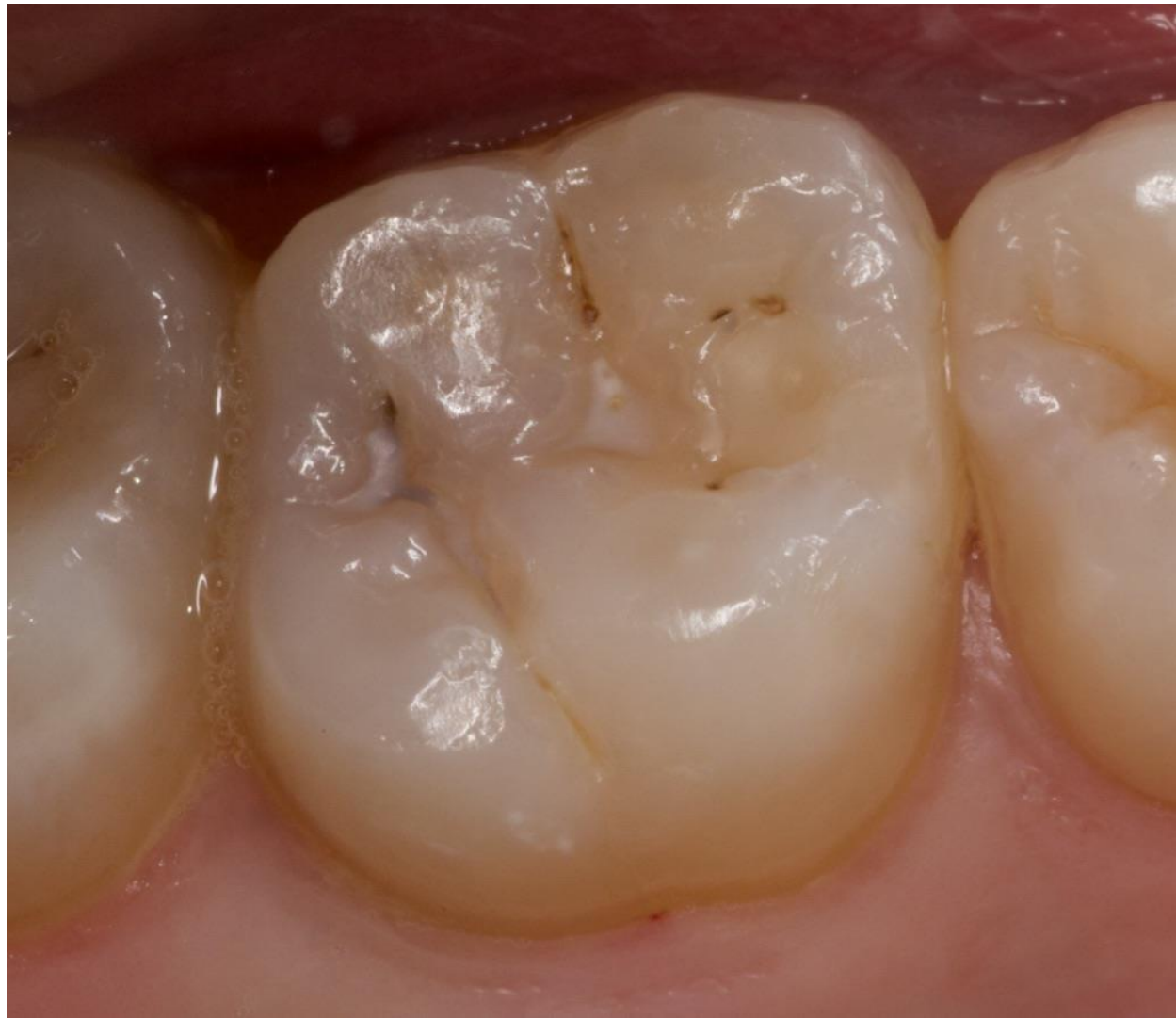12 month follow up



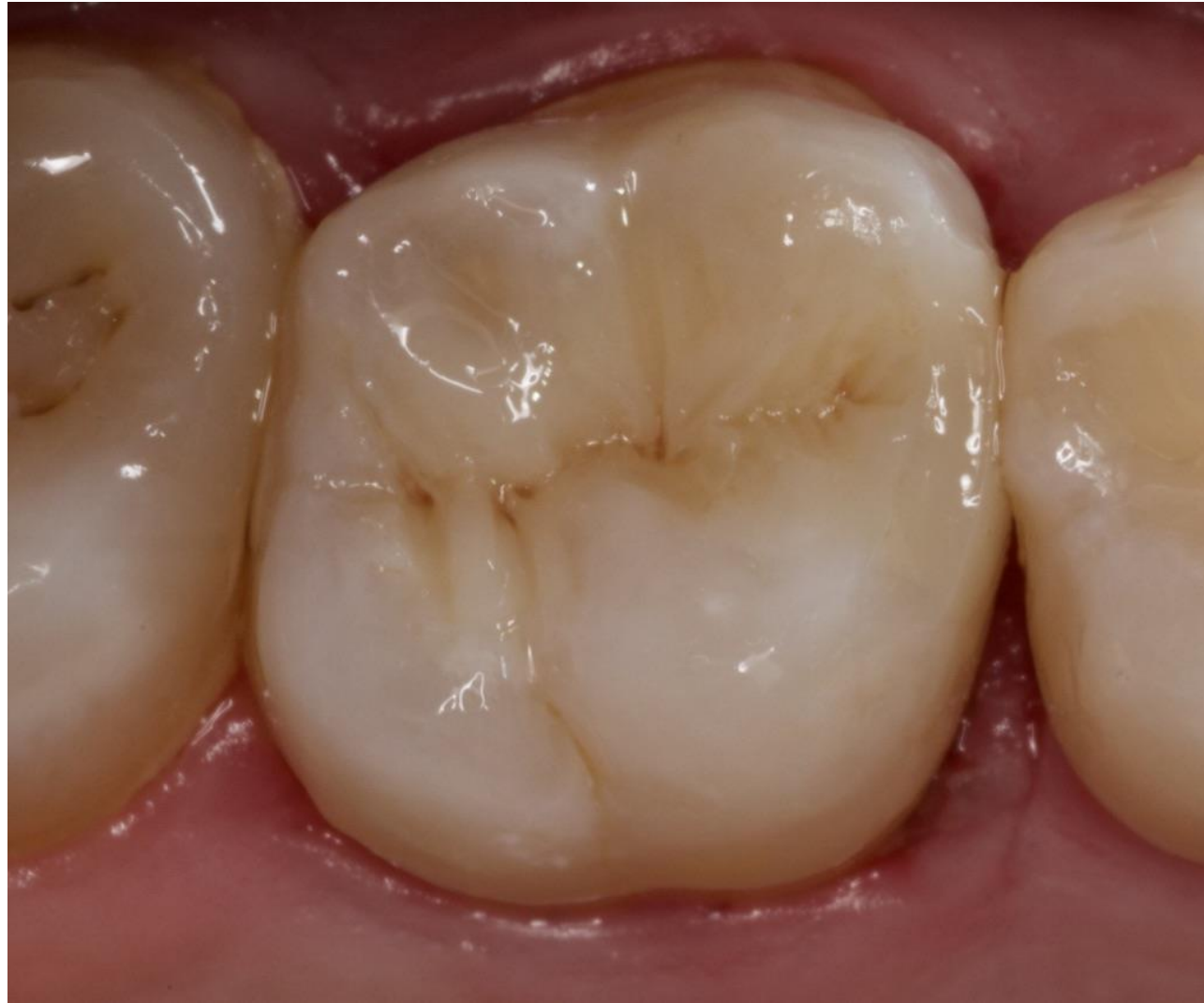18 month follow up

Case Report 5

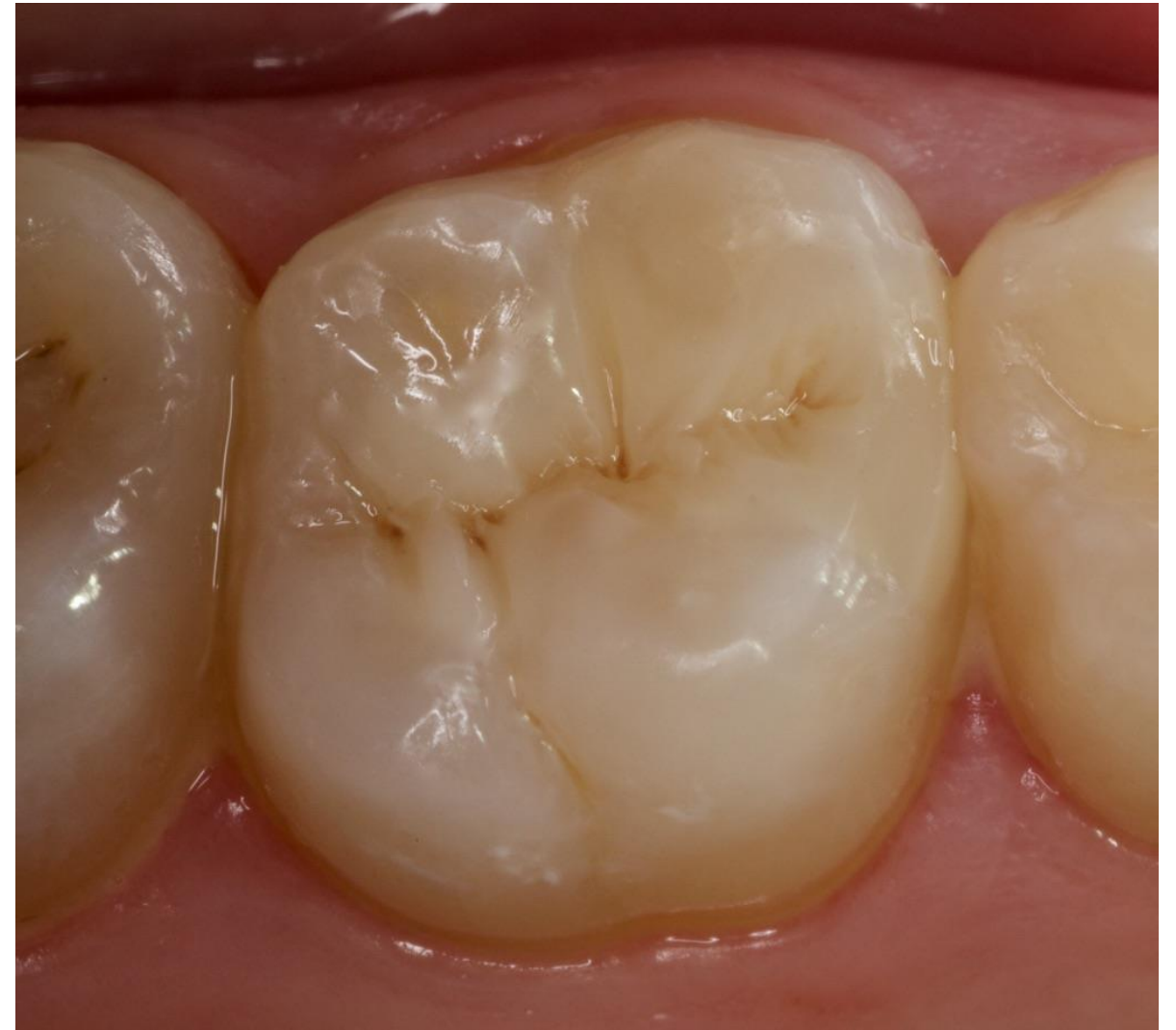Restoration of carious lesion on right maxillary molar (OM)



Final cavity preparation



Immediate post-op



17 month follow up

